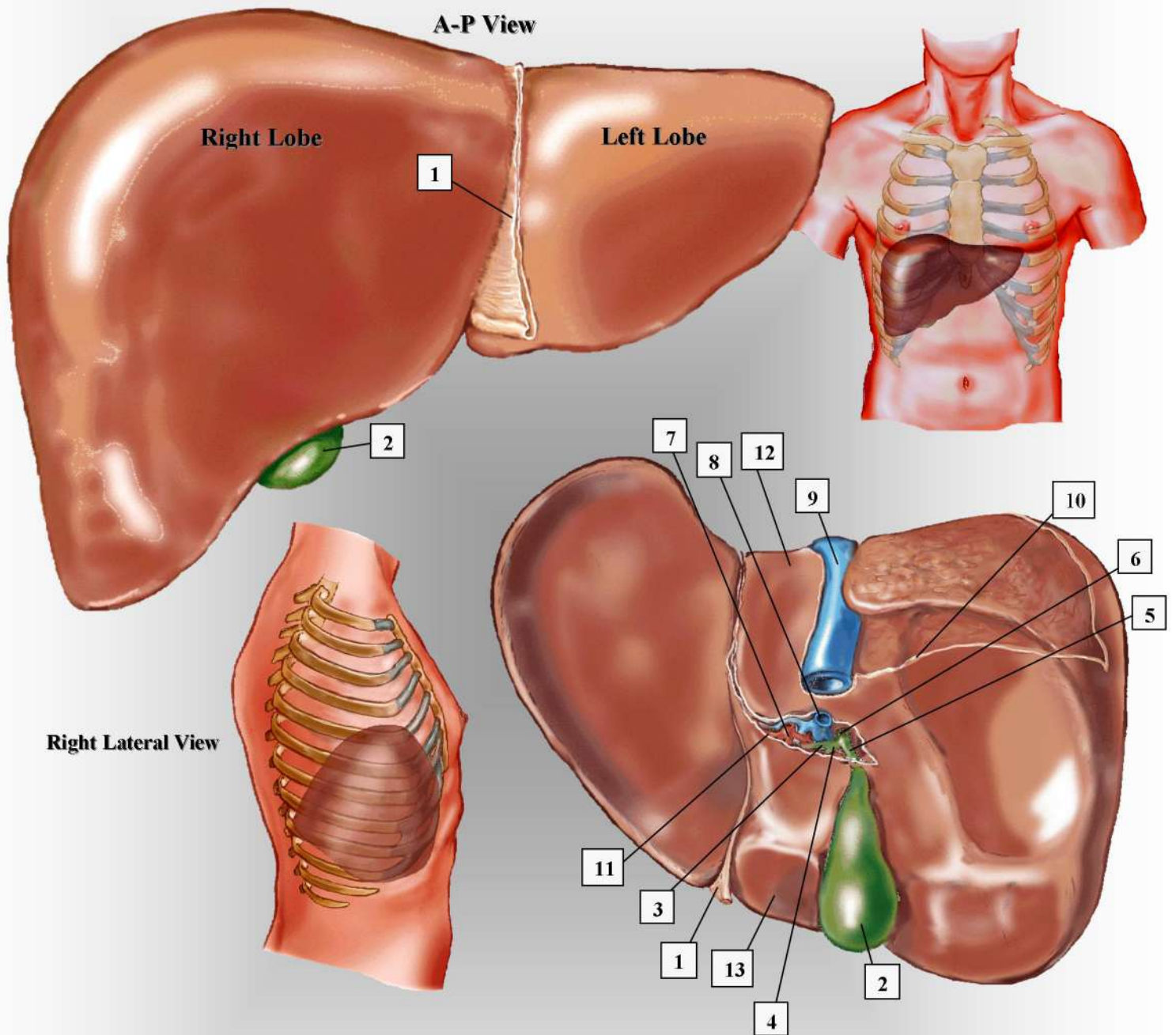


# THE LIVER



- |                                    |                     |                             |
|------------------------------------|---------------------|-----------------------------|
| 1. falciform ligament              | 5. cystic duct      | 9. inferior vena cava (IVC) |
| 2. gallbladder                     | 6. common bile duct | 10. fibrous hepatic capsule |
| 3. right & left intrahepatic ducts | 7. hepatic artery   | 11. porta hepatis           |
| 4. common hepatic duct             | 8. main portal vein | 12. caudate lobe            |
|                                    |                     | 13. quadrate lobe           |