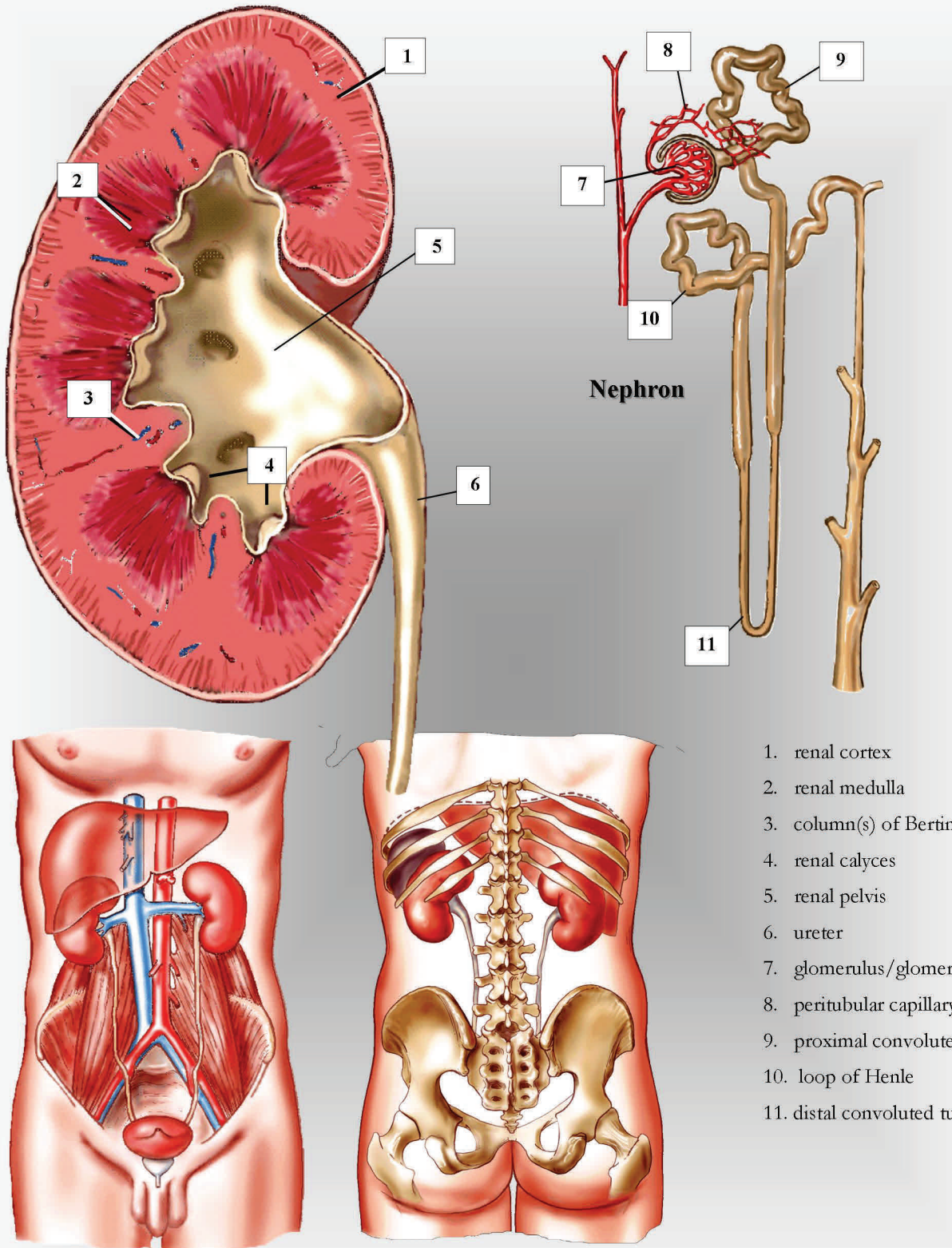


KIDNEY



1. renal cortex
2. renal medulla
3. column(s) of Bertin
4. renal calyces
5. renal pelvis
6. ureter
7. glomerulus/glomerular capsule
8. peritubular capillary network
9. proximal convoluted tubule
10. loop of Henle
11. distal convoluted tubule