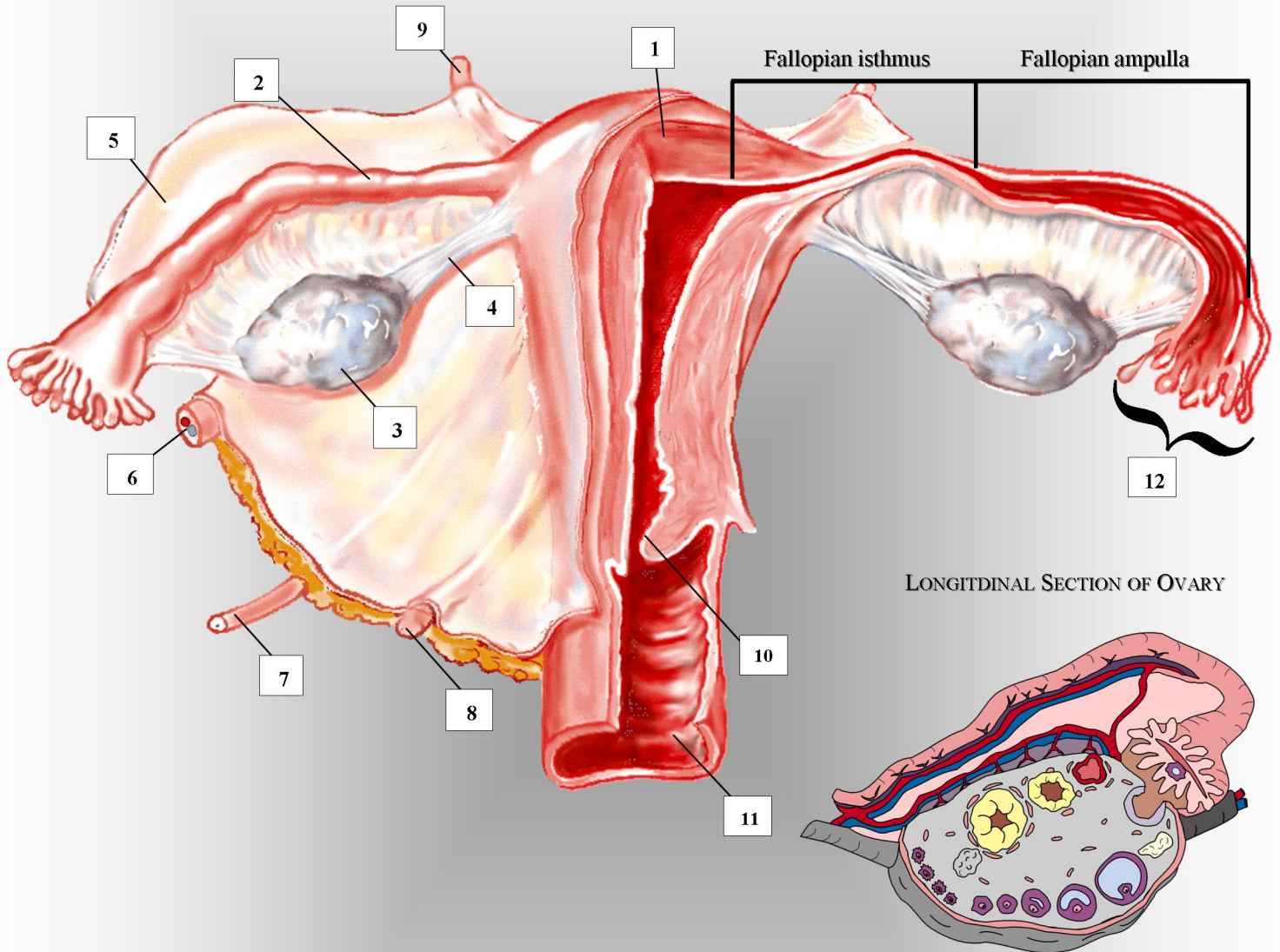


FEMALE REPRODUCTIVE SYSTEM



- | | | |
|--------------------------------|------------------------------|------------------------------|
| 1. uterine myometrium | 5. broad ligament | 9. superior uterine ligament |
| 2. fallopian tube | 6. ovarian artery & vein | 10. external cervical os |
| 3. ovary | 7. ureter | 11. vaginal canal |
| 4. ovarian suspensory ligament | 8. inferior uterine ligament | 12. fimbriae |