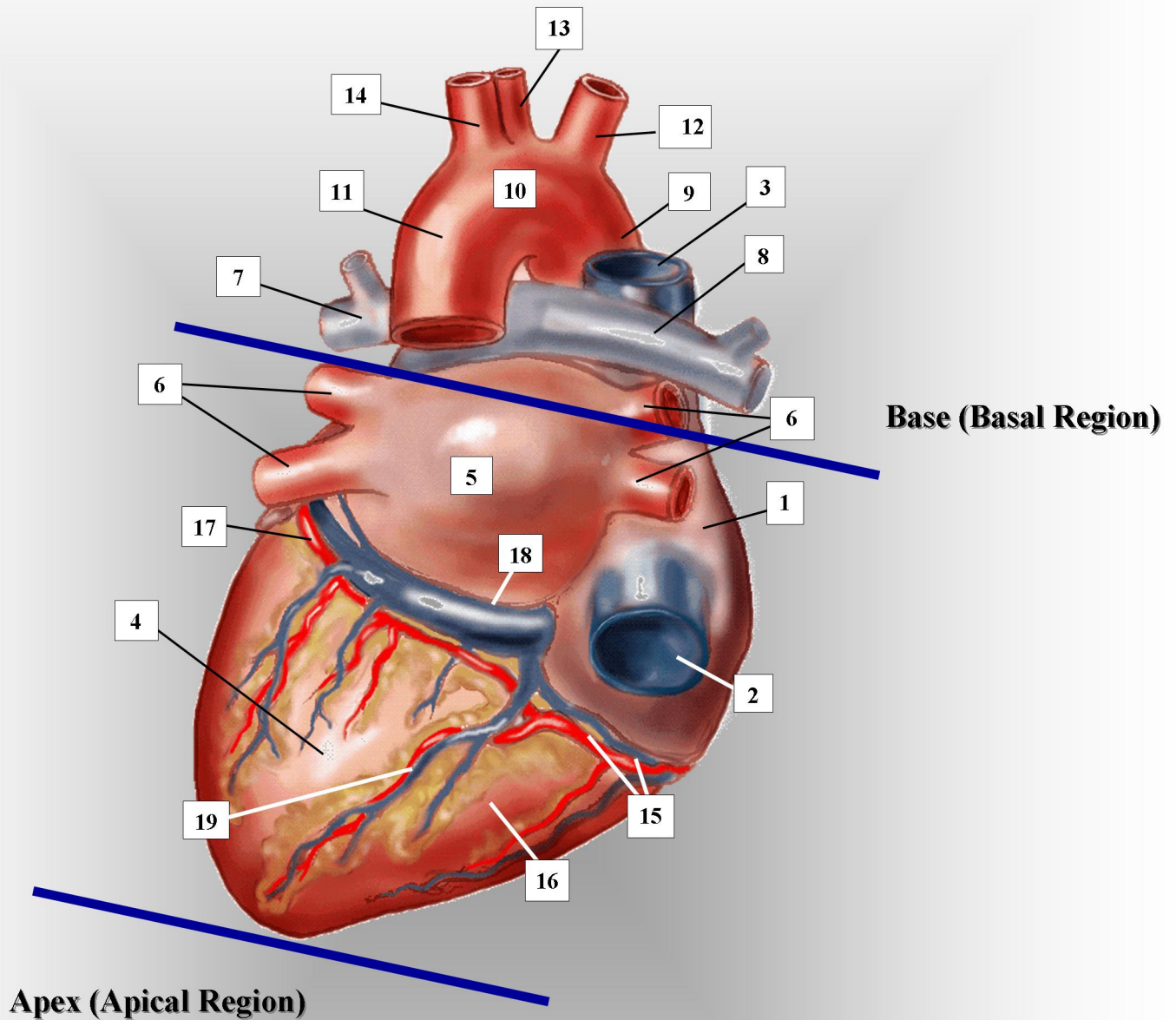


# ADULT HEART- POSTERIOR VIEW



- |   |                                       |  |
|---|---------------------------------------|--|
| 1. right atrium                           | 8. right branch of pulmonary artery   | 15. right coronary artery (and vein)                         |
| 2. inferior vena cava                     | 9. ascending aorta                    | 16. right ventricle  |
| 3. superior vena cava                     | 10. transverse aorta.                 | 17. left posterior circumflex coronary artery (and vein)     |
| 4. left ventricle                         | 11. descending aorta                  | 18. coronary sinus (great coronary vein)                     |
| 5. left atrium                            | 12. innominate/brachiocephalic artery | 19. posterior descending branch of the right coronary artery |
| 6. pulmonary veins (right and left pairs) | 13. left common carotid artery        |  |
| 7. left branch of pulmonary artery        | 14. left subclavian artery            |  |