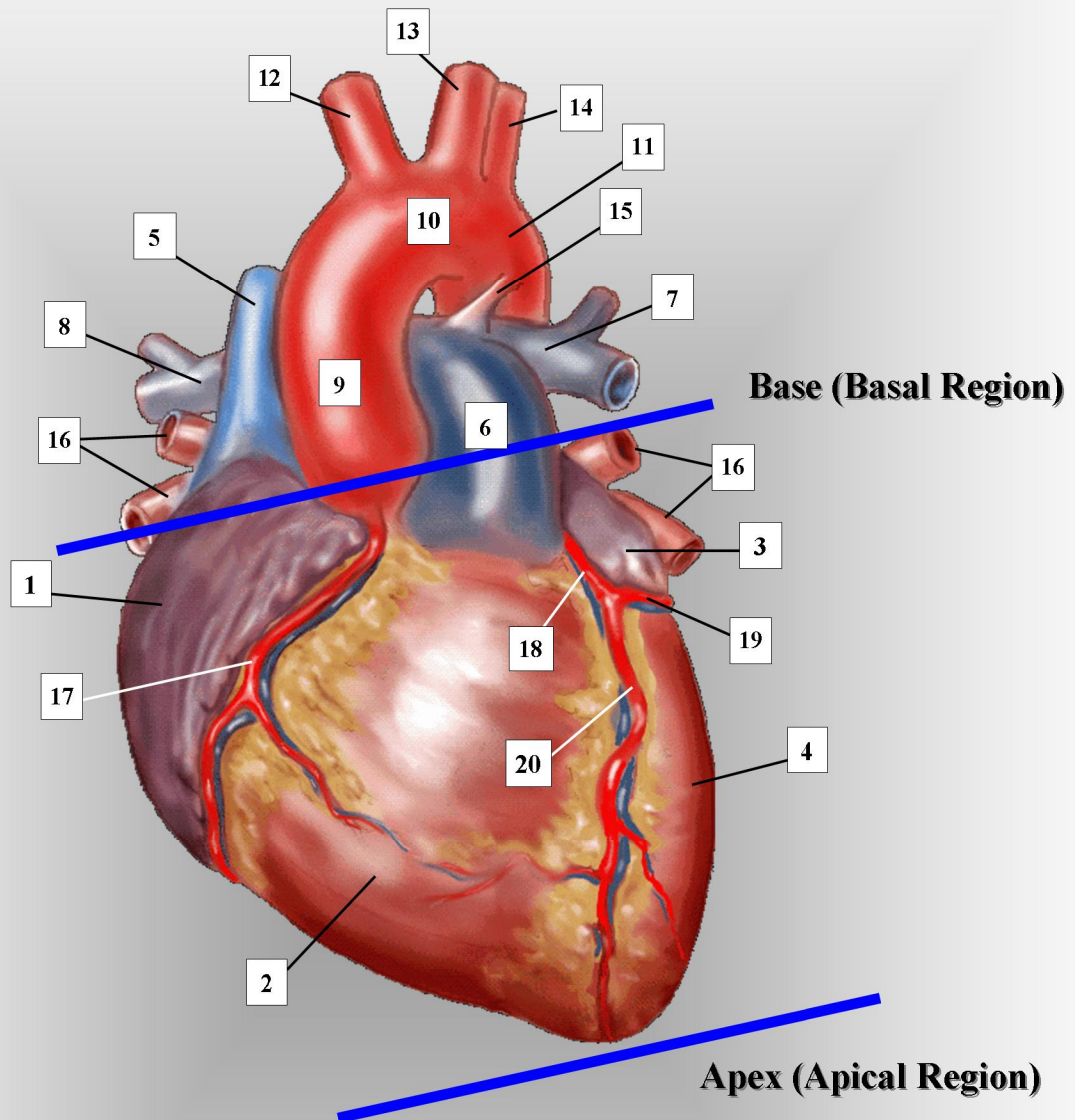


# ADULT HEART – ANTERIOR VIEW



- |                                    |   |   |
|------------------------------------|---|---|
| 1. right atrium                    | 8. right branch of pulmonary artery       | 15. ligamentum arteriosum (before birth: ductus arteriosus) |
| 2. right ventricle                 | 9. ascending aorta                        | 16. pulmonary veins (right and left pairs)                  |
| 3. left atrium                     | 10. transverse aorta.                     | 17. right coronary artery & vein                            |
| 4. left ventricle                  | 11. descending thoracic aorta             | 18. left main coronary artery and vein                      |
| 5. superior vena cava              | 12. innominate, or brachiocephalic artery | 19. left circumflex coronary artery and vein                |
| 6. main pulmonary artery           | 13. left common carotid artery            | 20. left anterior descending coronary artery and vein       |
| 7. left branch of pulmonary artery | 14. left subclavian artery                |   |