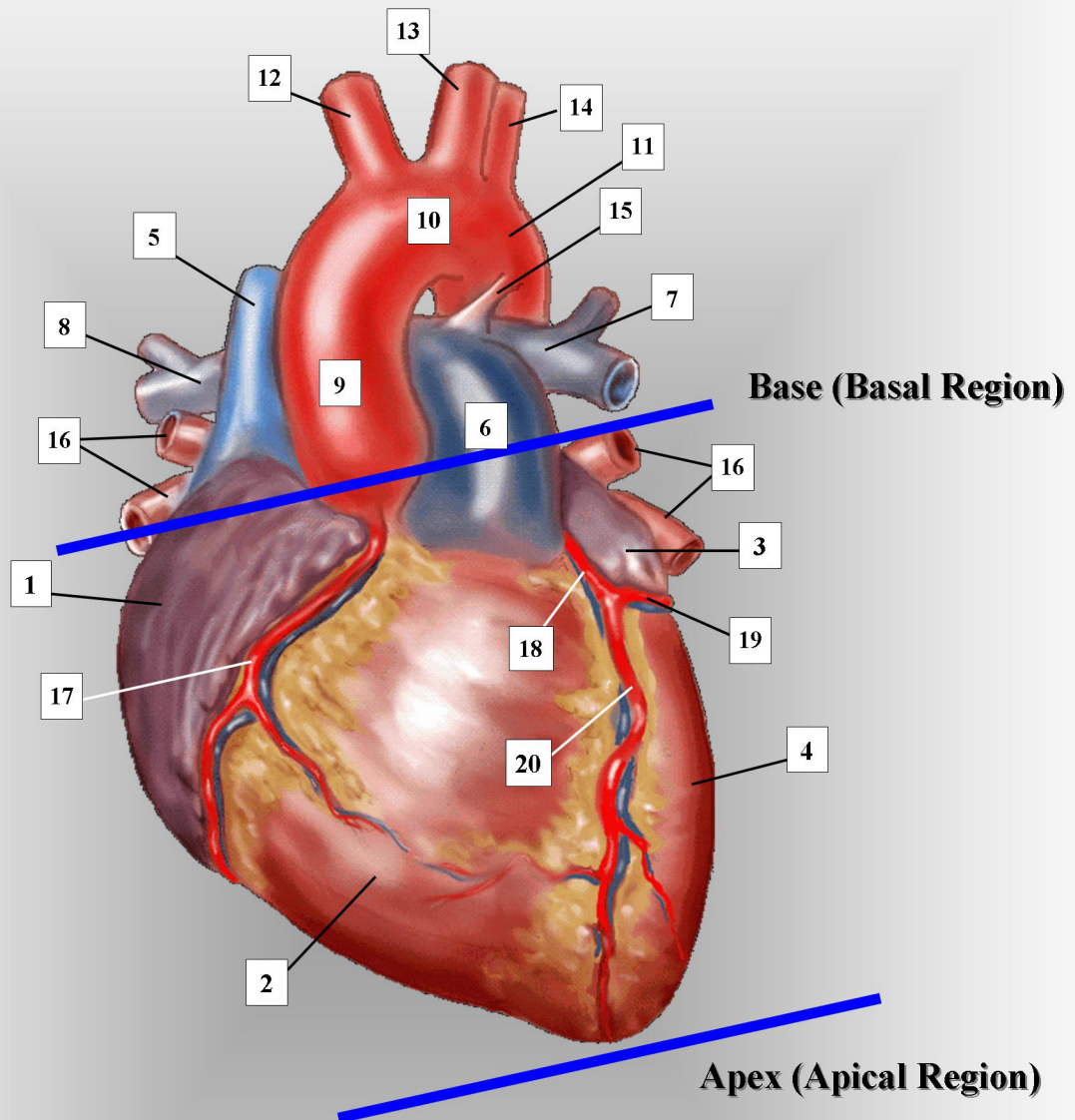


ADULT HEART – ANTERIOR VIEW



- | | | |
|------------------------------------|---|---|
| 1. right atrium | 8. right branch of pulmonary artery | 15. ligamentum arteriosum (before birth: ductus arteriosus) |
| 2. right ventricle | 9. ascending aorta | 16. pulmonary veins (right and left pairs) |
| 3. left atrium | 10. transverse aorta. | 17. right coronary artery & vein |
| 4. left ventricle | 11. descending thoracic aorta | 18. left main coronary artery and vein |
| 5. superior vena cava | 12. innominate, or brachiocephalic artery | 19. left circumflex coronary artery and vein |
| 6. main pulmonary artery | 13. left common carotid artery | 20. left anterior descending coronary artery and vein |
| 7. left branch of pulmonary artery | 14. left subclavian artery | |

