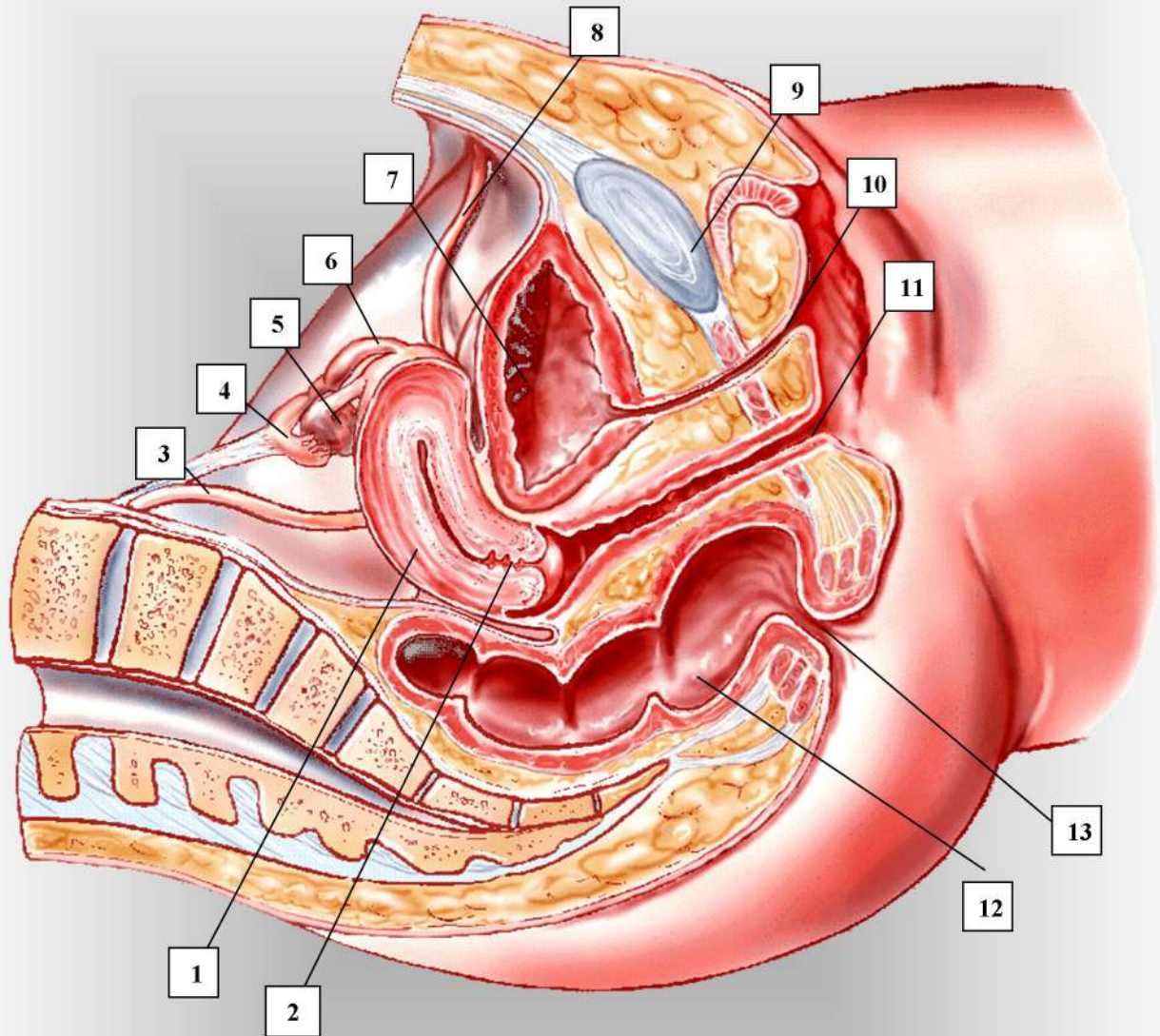


FEMALE PELVIS



- | | | |
|--------------------------------|-------------------|--------------|
| 1. uterus | 5. ovary | 9. symphysis |
| 2. cervix | 6. broad ligament | 10. urethra |
| 3. ovarian suspensory ligament | 7. bladder | 11. vagina |
| 4. fallopian tube | 8. ureter | 12. rectum |
| | | 13. anus |

