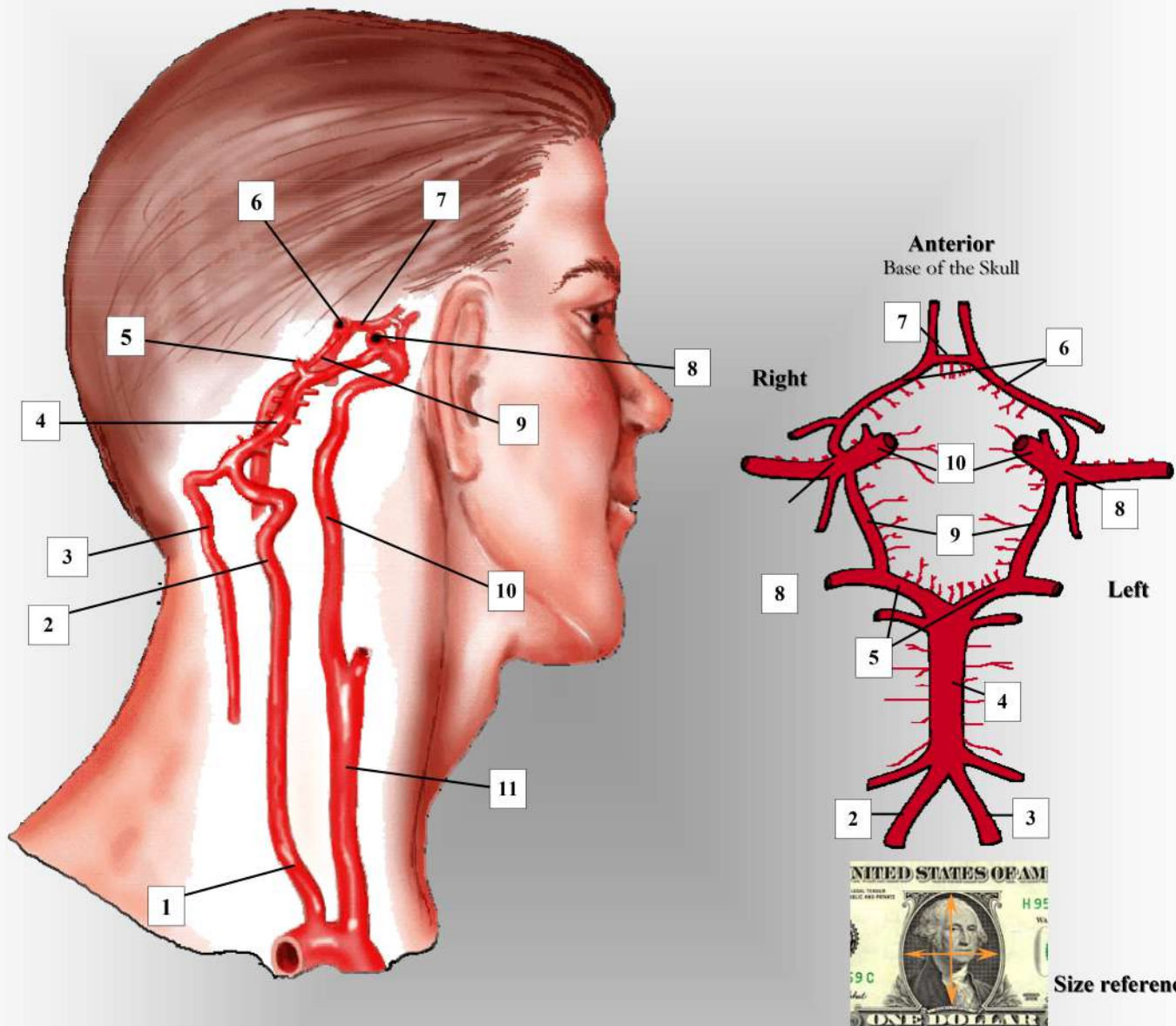


THE CIRCLE OF WILLIS: INTRACRANIAL CEREBROVASCULAR ARTERIAL ANATOMY



- | | |
|--------------------------------|-------------------------------------|
| 1. rt. subclavian artery | 6. anterior cerebral arteries |
| 2. rt. vertebral artery | 7. anterior communicating artery |
| 3. lt. vertebral artery | 8. middle cerebral arteries |
| 4. basilar artery | 9. posterior communicating arteries |
| 5. posterior cerebral arteries | 10. internal carotid arteries |
| 11. common carotid artery | |

